

Morphometric Studies on the Skull of the Australian Domestic Cat (*F. catus*) and its Clinical Implications for Regional Anesthesia

A.S.Saber^{1,2}; T. Caceci³; B.Gummow^{2,4} and K.Johns²

¹ Faculty of Veterinary Medicine, University of Sadat City, Sadat City, Egypt

² Discipline of Veterinary Sciences, College of Public Health and Veterinary Sciences, James Cook University, Townsville, Australia.

³ Department of Biomedical Sciences Virginia Tech/Carilion School of Medicine Roanoke, Virginia, USA 24016

⁴ Faculty of Veterinary Sciences, University of Pretoria, Pretoria, South Africa

With 10 figures & 6 tables

Received December 2015, accepted for publication Feb. 2016

Abstract

Understanding of orbital and periorbital anatomy is critical to the diagnosis and therapy of orbital disorders. Twenty-six cat heads were obtained from the dissecting room in the Discipline of Veterinary Sciences, College of Public Health and Veterinary Sciences, James Cook University, Townsville, Australia for use in this study. After macerating the heads and cleaning the skulls they were grouped by morphology into 15 round-headed and 11 flat-headed skulls. In the flat-headed group, the skulls were elongated with a prominent constriction between the cranium and facial bones and a prominent external sagittal crest, which extended from the nuchal crest. Furthermore, complete to nearly complete fusion of the zygomatic process of the frontal bone with the zygomatic arch resulted in a complete bony orbit.

The skulls were radiographed, and a total of 32 parameters measured for each group: the skull, cranium, face, orbit and mandible were compared and analyzed. The sites of injecting the infra-orbital, mandibular alveolar and mental nerves were confirmed in both groups of cat skulls.

We conclude that old age plays a major role in forming the skull shape (rounded versus flattened) and closure of the orbital rim.

Keywords: Morphometry, Australian cats, Flat-headed skull, Round-headed skulls.

Introduction

After finishing an anatomy practical, 26 cat heads were macerated for making skeletons. It was noticed that eleven out of the 26 skulls had different morphological features than the other 15. They were elongated, with a prominent constriction between the

cranium and facial bones and a prominent external sagittal crest, which extended from the nuchal crest. Furthermore, they showed a complete to partially fused zygomatic process of the frontal bone with the zygomatic arch, resulting in a complete bony orbit (Figs 1-3).

These observed features characterize the skulls of the flat-headed cats native to the tropical forests of Malaysia, Borneo and Sumatra but which have been listed as extinct in 1985⁽¹⁾. The Australian Government's Department of Sustainability, Environment, Water, Population and Communities mentioned, for management purposes, that cats in general are divided into three categories: domestic (those owned and cared for), stray (those found roaming cities, towns and some rural holdings) and feral cats which survive without any human contact or assistance. These three groups are all of the same species (*Felis catus*), but individual cats may move between the categories⁽⁴⁾.

There are now an estimated 2,7 million domestic cats and over 18 million feral cats in Australia. By 2006, 26% of households had a domesticated cat (Wikipedia, retrieved 25/7/2014). These skulls belonged to cats in the domestic category as they were donated to the Anatomy & Pathology Discipline by the owners.

Hence, a question is raised about the presence of two types of cat skulls, and the anatomical similarities of the flat-headed cat skulls of Malaysia, Borneo and Sumatra to those of the

Australian house cats of this study. Or is the similarity simply a matter of age differences?

Most articles and reports on the domestic cats in Australia do not address the anatomy of the different cat breeds.

They mentioned only their number (46 recognized cat breeds)⁽⁵⁾, general morphology and the tail length, the colour and stripes of the coat hair⁽⁶⁾.

The aim of this work is to establish a morphometric database on these flat-headed and round-headed Australian cats and to provide guidance in the use of these measurements for diagnosing and treating orbital and peri-orbital disorders (orbital trauma, tumors and abscesses); and to localize sites for a variety of nerve blocks for surgery and dentistry.

Material and Methods

Twenty-six skulls, including the mandibles, of Australian domestic house cats were macerated and prepared in the Discipline of Anatomy and Pathology, Discipline of Veterinary Sciences, College of Public Health and Veterinary Sciences, James Cook University, Townsville, Australia. Neither the sex nor the age of the cats was recorded.

The skulls were prepared using the boiling maceration technique for skeleton preparation described by Simoens et al. (1994). The skulls were divided according to their morphology into two groups: flat-headed group (11 skulls) and a round-headed group (15

skulls). Before preparing the skulls, twelve heads were x-rayed in the latero/medial and dorso/ventral positions using the parameters kV 80 and 58 mAs, to predict the type of the skulls from the images before preparing the skulls.

The following external measurements were taken from both groups as described by Sarma (2006), Yahaya et al. (2012) and Monfared (2013).

Skull Parameters Measured (Fig 4)

- 1) Skull length: Distance between the highest point of the parietals to the middle of the rostral margin of the incisive bone.
- 2) Skull width: Distance between two zygomatic arches.
- 3) Skull weight: Weight of the skull (excluding the mandible).

Cranial Parameters Measured (Figs 4,5)

- 4) Cranial length: Distance from the central point of the fronto-nasal suture to the middle point of the nuchal crest.
- 5) Cranial width: Maximum distance between the highest points of the parietal bones.
- 6) Foramen magnum height: Mid-vertical height of the foramen magnum.
- 7) Foramen magnum width: Largest width of the foramen magnum.
- 8) Cranial capacity.

Facial Parameters Measured (Fig 6)

- 9) Facial length: Distance from the

fronto-nasal suture to the center of the incisive bone.

- 10) Facial width: Distance between the caudal extents of the orbital rims.

Orbital Parameters Measured (Figs 6,7)

- 11) Orbital length: The perpendicular distance between the supraorbital and infra orbital margins of the orbit.
- 12) Orbital width: The horizontal distance between the rostral and caudal margins of the orbital rim.
- 13) Inter-orbital distance: At rostral level; Distance between the junction of the fronto-lacrimal sutures of either side at the rostral margin of the orbit.
- 14) Inter-orbital distance: At the middle level; Distance between the supraorbital borders of orbit on either sides.
- 15) Inter-orbital distance: At the caudal level; Distance between the junctions of the zygomatic bone at the caudal margin of the orbit on either sides.
- 16) Infra-orbital foramen distance: Facial width between the supraorbital foramina.
- 17) Infra-orbital canal to the root of the (canine) alveolar tooth.
- 18) Infra-orbital canal to the root of the first premolar tooth.
- 19) Orbital capacity.

Mandibular Parameters Measured (Figs 8,9)

- 1) Mandibular length: Distance between the level of the rostral part of the alveolar root of the incisor to the level of the caudal border of the mandible.
- 2) Mandibular weight (in gm.)
- 3) Distance between caudal mental foramen and caudal mandibular border.
- 4) Distance between caudal mental foramen and rostral mental foramen.
- 5) Distance between rostral mental foramen and incisor root.
- 6) Distance between mandibular foramen and caudal border of the mandible.
- 7) Distance between mandibular foramen and angle of the mandible.
- 8) Distance between mandibular foramen and ventral border (base) of the mandible.
- 9) Maximum mandibular height: Distance between the basal point of the mandible to the highest level of the coronoid process.
- 10) Condylod process to the ventral border (base) of the mandible.
- 11) Maximum height of coronoid process (Condylod fossa to height of mandible).
- 12) Diastema length: Distance from the lateral alveolar incisor root to first cheek tooth (P).
- 13) Inter-mandibular distance at the level of the last cheek tooth (M).

For measuring the orbital capacity, foramina opening into or with the orbital cavity were plugged with plasticine (plastic clay) and /cotton wool. The communication between the orbital cavity and temporal fossa was blocked with cotton wool and whole orbital cavity was lined with a very thin tissue paper. Then the cavity was filled with mustard seed to the level of the orbital rim. The contents were emptied and measured in a measuring cylinder.

For measuring the cranial capacity, all the foramina of the cranial cavity were plugged with cotton wool. The cavity was then filled with mustard seeds through the foramen magnum up to its brim. The mustard was then emptied into a measuring cylinder to get the cranial volume.

The cranial, facial, orbital and skull/cephalic indices were determined using the following equations mentioned by Miller et al. (1964).

a) *Cranial index*

$$= \frac{\text{cranial width}}{\text{cranial length}} \times 100$$

b) *Facial index* = $\frac{\text{facial width}}{\text{facial length}} \times 100$

c) *Orbital index* = $\frac{\text{orbital width}}{\text{orbital length}} \times 100$

d) *Skull/cephalic* = $\frac{\text{skull width}}{\text{skull length}} \times 100$

Data Analysis

Data was stored and analyzed using Microsoft Excel 2010. The craniometrical measurements were taken using a normal caliper and a digital scale was used for weighing. Photographs were taken with a Samsung WB 700

digital camera. Nomina Anatomica Veterinaria (2005) was utilized for denominating the anatomical terms in the study.

Results

In the present study, the skull mean length of the domestic flat-headed and round-headed skulls was 10.1 ± 0.9 , 8.2 ± 0.72 cm, the mean cranial length was 7.8 ± 0.6 , 6.24 ± 0.53 cm, while the mean facial length was 2.3 ± 0.3 , 1.9 ± 0.27 cm respectively.

The mean skull width was 7.2 ± 0.4 , 5.83 ± 0.63 , the mean cranial width was 4.3 ± 0.2 , 4.14 ± 0.22 cm and the mean facial width was 6.7 ± 0.3 , 5.43 ± 0.02 cm in both skull types respectively (Tables 1,2).

The mean cranial index in the flat-headed skulls was 56 ± 4 and in the round-headed skulls was 66.58 ± 4.94 , whereas the mean facial index was 298.1 ± 34 and 279.77 ± 31.87 respectively (Tables 5A, B).

Three shapes of the foramen magnum were detected: round, oval and triangular (Fig 10). The mean height of the foramen magnum was 1.1 ± 0.2 , 1.04 ± 0.08 cm, while the mean width was 1.4 ± 0.2 , 1.3 ± 0.2 cm in the flat- and round-headed cat skulls respectively. The mean foramen magnum index was 128 ± 30 and 128 ± 18.8 in both types respectively.

The mean orbital index was $86.21 \pm 9.1 \pm$ and 92.49 ± 7.13 respectively. The mean skull (cephalic) index was

71.1 ± 4.4 and 71.28 ± 2.28 respectively (Table 5A, B).

The mean distance between the infra-orbital foramen and maxillary canine root & between the infra-orbital foramen and the premolar I root was 1.6 ± 0.4 , 1 ± 0.2 cm & 0.9 ± 0.2 and 0.7 ± 0.2 cm in the flat- and round-headed cat skulls respectively (Table 1,2).

The mean mandibular length and height was 6 ± 0.58 , 2.97 ± 0.27 cm & 4.43 ± 0.58 , 2.17 ± 0.25 cm in the flat- and round-headed skulls respectively. The mean distance between the mandibular foramen and the caudal border of the mandible was 1.3 ± 0.4 , 0.9 ± 0.2 cm, while the mean distance between the mandibular foramen and the ventral border of the mandible was 0.7 ± 0.2 , 0.4 ± 0.1 cm in the flat- and round-headed skulls respectively (Tables 3,4).

The distance between the rostral mental foramen and the incisor root was 0.9 ± 0.1 and 0.7 ± 0.2 cm in the flat- and round-headed skulls respectively (Tables 3,4).

From the measurements of both cat skull types we can determine that anesthetic blockage of the infra-orbital nerve could be achieved by injecting a local anesthetic solution 1.0-1.6 cm dorso-caudal to the maxillary incisor tooth in both the round- and flat-headed cats respectively.

The results of the present study also clarified that for better local anesthetic blockage of the mandibular alveolar nerve of cats the needle should be

introduced 0.9 to 1.3 cm from the ventral border of the mandible in round-headed cats and about 0.9 cm from the angle of the mandible in flat-headed cats. The mental foramen could be reached for anesthetic blockage of the mental nerve about 0.7-0.9 cm caudal to the mandibular incisor.

Discussion

Skull morphology and development

The two parts of the cat's mandible do not fuse completely allowing some movement³. Cats have a weak external sagittal crest arising from the nuchal crest. The dorsal margin of the orbit is formed by the orbital ligament, which is ossified. The inter-parietal bone does not fuse entirely in the adult³. This description agrees to some extent with the findings of this study, in different degrees: it applies to the flat-headed skulls but not to round-headed skulls. In addition, the weak external sagittal crest is found only in the round-headed skulls and is absent in the flat-headed cat skulls.

Koenig and Liebisch (2007) mentioned that in carnivores the dorsal margin of the orbit is formed by the orbital ligament, a structure which is often ossified in the cat. Coulson and Lewis (2008) added that in a Siamese cat 15 years old, the orbital ligament was ossified; and that it was only 0.3 cm long in immature but 1.3 cm long in very old cats after fusion with the zygomatic arch (Ashdown, unpublished). Slat-

ter and Basher (1993) confirmed that the dorsal wall of the feline orbit is almost entirely bone because the zygomatic process of the frontal bone and the frontal process of the zygomatic come into proximity. They mentioned also that in the dog, the dense collagenous orbital ligament between the zygomatic process of the frontal bone and the frontal process of the zygomatic forms the dorsolateral wall of the orbit.

In European wildcats, which are not the same species as the domestic cats, Stefen and Heidecke (2012) found that most postnatal shape changes in the skull occur in its caudal part, including the development of the nuchal and sagittal crest, the change of the relative position of the frontoparietal suture, the broadening of the skull at the postorbital process and in the zygomatic width, and elongation of the nasals.

Important skull changes occur in carnivores by development of superstructures related to the masticatory apparatus e.g. temporal ridges and a sagittal crest (Carcia-Perea, 1996). The same author mentioned that although temporal ridges and the sagittal crest show apposite patterns of changes developmentally, their consequences are similar from the functional point of view. The migration and expansion of the origin margins of the temporalis muscle with age would allow an increase of the muscle mass implying an increase in the number of fibers

(Moore, 1981) very likely resulting in a more powerful action (Bock, 1974).

Carcia-Oerea (1996) studied postnatal skull development in four species of Lynxes and categorized four degrees of ossification: borders of adjacent bones separated, borders of adjacent bones contacting, active ossification occurring in the synchondrosis and complete ossification of the synchondrosis. She mentioned also that long sagittal crests are associated with narrow lyres (the surface delimited by temporal ridges, so called by this author), and vice versa. Moreover, she identified four types of sagittal crest: in the juvenile stage, temporal ridges are present, but there is no sagittal crest; a sagittal crest that is poorly developed and restricted to the interparietal region; and a sagittal ridge that is well developed, occupying total length of parietal suture; no lyre present. These four types of sagittal crest were identified in the present study. The four degrees of ossification were also detected in the flat-headed cat's orbital ligaments, although some of them were of young cats as their teeth denote.

Zuccarelli (2004) described different morphological measurements between the skulls of wild and captive lions. He mentioned that to compensate the higher degree of strain upon regions of the skull, wild specimens showed an increase in skull surface area, which permits greater distribution of strain as well as larger areas for muscle attachment. The skull

growth and development in *P. leo* is subject to variation not only in different populations, but also even between individual from neighboring prides or from the same pride (Smuts et al., 1978). These variations are believed to be the result of different foods available to individuals as well as prides and populations (Zuccarelli, 2004). Taking these results in consideration, feral cats would also show similar variations in these parameters than the domestic cats.

The infra-orbital nerve is a branch of the ophthalmic division of the trigeminal nerve. It passes through the infra-orbital canal and exits the infra-orbital foramen to supply sensory innervations to the middle part of the face (Pasquini et al., 2007). The anesthetic blockage of this nerve is achieved by injecting the local anesthetic solution 1.0-1.6 cm dorso-caudal to the maxillary incisor tooth in the round- and flat-headed cats.

Techniques used

Using the mustard seeds for measuring the cranial and orbital capacities is preferred by many authors because of the rounded shape and small size of the seeds (Saber, 1989; Sarma, 2006). However, some authors used sesame seeds (Rao, 1967) and rice grains (Olopade and Onwuka, 2005) and sand (Mihayalov et al., 2013). Some other authors used more modern techniques such as computed tomographic images and scanograms as well as x-ray images of live animals for measuring. Not all parameters es-

timated by modern techniques are accurate, as they are measured on plane surfaces. Cranial cavity and orbital cavity are examples of using the traditional methods (Mustard seeds of this study) in estimating their volume.

Morphometric measurements

Several authors have previously studied the skull morphometry of many animal species (Monfred et al., 2013 a-k; Karimi et al., 2011, 2012; Sarma, 2006; Olopade et al., 2005; Sarma and Sarma, 2002; Onar et al., 2001; Onar, 1999; Regedon at al., 1991, 1992, Saber, 1989; Sandhu and Dhingra, 1986; Brehm at al., 1985; Eoa, 1967 and Miller at al., 1964), of the African giant rat (Olude and Olopade, 2010), of the yak (Sudhakar and Sharma, 1998).

Stefen and Heidecke (2012) mentioned that wildcats were distinguished from domestic cats by cranial volume and cranial index. According to Piechocki (1990), the cranial volume of wild cats ranges from 32.5 – 50 cm³ and for domestic cats from 20-25 cm³; hence, a cranial volume of >35 cm³ it can be used to identify wildcats. Moreover, for cats with cranial volume of 32-35 cm³ the cranial index (greatest total skull length: cranial volume) must be calculated to clearly identify the type of cat (Schauenberg, 1969). Accordingly, the parameters of the flat-headed skulls of this study is very near to that of cats of the wild or feral origin, although wild and feral cats are different species, (cranial volume 21.5-38 with average of 30 ± 5.2 cm³),

while the round-headed were of the domestic type (cranial volume 14.5-31.6 with average 25.2±3.8 cm³).

In comparison, domestic cats have a cranial index (CI) greater than 2,75, representing a smaller cranial capacity, which is commonly associated with domesticated animals (Schauenberg, 1969, Groves, 1999). Higher value of the cranial capacity of wildcats is induced by the frontal part of the skull, which is more arched (Krueger et al., 2009).

Stcharski et al. (2010) reported that increase of the length and the breadth of visceral-cranium takes place not only during cat maturation but also after this period in adult animals. They mentioned also that cranial indices show that the ratio of the total cranium length does not change in three age stages of domestic cats.

Foramen magnum

The foramen magnum was round, oval or triangular in shape in both flat- and round-headed cat skulls of the present study. Chethan et al. (2011) mentioned that the foramen magnum shapes in 53 human skulls were determined as round in 22.6% of cases, egg shape in 18.9%, tetragonal in 18.9%, oval in 15.1%, irregular in 15.1%, hexagonal in 5.6% and pentagonal in 3.8% of the cases. In the 20% of skulls Burdan et al. (2012) mentioned eight shapes were described for the foramen magnum in human skulls; circular, two semicircular, heart-like, wide oval, bi-rounded oval, ventrally wide oval, bi-pointed

oval and dorsally convergent oval. On the other hand Muthukumar et al. (2005) said that in 46% of the studied specimens, when the foramen magnum index in human is equal to or more than 1.2, the foramen was found to be oval.

The mean foramen magnum width and height of the flat-headed and round-headed cat skulls of this study were 1.4 ± 0.2 , 1.1 ± 0.2 and 1.3 ± 0.2 , 1.1 ± 0.2 cm respectively. These values are very close (1.23 cm and 1.23 cm) to that given in the same animal by Uddin et al. (2013).

The foramen magnum index of the domestic cat was 90.72 which is similar to that of the mole rat 88.41 (Ozkan, 2007) and Pekingese dog 93.4; (Janeczek et al., 2011) and higher than the rabbit 74.68 (Kahvecioglu et al., 2000) and African giant rat 81.42 (Olude et al., 2009), where the foramina magna were relatively wide. However, the foramen magnum index was relatively higher in the West African Dwarf goat 106.82 (Chroszez et al., 2006). The foramen magnum index of the flat- and round-headed cat skull of this study was 127.27 and 118.18 respectively.

Yahaya et al. (2014) observed three distinct patterns of the foramen magnum in camels. The dorsal border of the foramen presented a smoothly curved bony margin (Type I), a small, ventrally directed, median bony protrusion (Type II) or a dorsal notch (Type III). Neither of these types was met with in the cats of this study.

Mandible measurement

The mean mandibular length and height of the cats of this study was 6 ± 0.6 , 4.4 ± 0.6 & 2.9 ± 0.3 , 2.2 ± 0.3 cm in the flat- and round-headed cats respectively.

Monfared (2013i) gave 8.3 ± 1.03 and 3.7 ± 0.59 cm as length and height for the Persian cat's mandible. Barroso et al. (2009) mentioned in goats 51.47 ± 4.02 mm as length of non-defined cat breed's mandible. Samul et al. (2013) mentioned in goats 13.61 ± 1.73 and 8.5 ± 0.53 cm for the length and height of the mandible respectively. The mandibular length and height measured for koala, wombat and wallaby were 9.8 ± 5.66 , 12.7 ± 8.89 & 9.9 ± 5.72 cm, 6.8 ± 3.93 & 8.05 ± 5.69 , 4.1 ± 2.37 cm respectively (Saber, 2015).

The inferior alveolar nerve is a branch of the mandibular division of the trigeminal nerve and is sensitive in nature. It runs about 10 mm before its emergence into the mandibular foramen, passing in the mandibular canal and exiting from the mental foramen as the mental nerve (Getty, 1986 and Onar, 1999). Anesthetic blockage of the inferior alveolar nerve promotes the anesthesia of the premolar, canine and incisor teeth, skin, cheek mucosa and lower lip (Muir, 2001). The present study clarified that for better local anesthetic blockage of the mandibular alveolar nerve of cats the needle should be introduced 0.9 to 1.3 cm from the ventral border of the mandible and about 0.9 cm from the angle

of the mandible in the round- and flat-headed cats respectively. The mental foramen could be reached for anesthetic blockage of the mental nerve about 0.7-0.9 cm caudal to the mandibular incisor.

Moreover, the complete bony orbit that characterizes the flat-headed skulls should be considered prior to performing orbital surgery (Slatter and Basher, 2003).

Conclusion

There are two morphological categories of cat skulls in Australia, flat- and round-headed. To confirm the wild or Asian origin of the flat-headed ones more study is needed, perhaps DNA typing and comparisons to Asian and/or European or African population.

- The infra-orbital nerve can be blocked by introducing the needle 1.0 to 1.6 cm caudo-dorsal to the maxillary canine tooth in the round- and flat-headed cats respectively.
- For better local anesthetic blockage of the mandibular alveolar nerve of cats, the needle should be introduced 0.9 to 1.3 cm from the ventral border of the mandible and about 0.9 cm from the angle of the mandible in the round- and flat-headed cats respectively.
- The mental foramen could be reached for anesthetic blockage of the mental nerve about

0.7-0.9 cm caudal to the mandibular incisor.

References

- Alpak, H. (2003):** Morphometry of the mandible of German shepherd dog (Alsatian) puppies using computed tomographic analysis. *Israel Journal of Veterinary Medicine*. Vol. 58 (1): 15-17.
- Barroso, R.M.V.; Ferreira, F.A.; Silva, R.M.; Lima, E.M.M. (2009):** Morphometric analysis of the mandibular foramen of cats (*Felis catus*, Linnaeus 1758) with no defined breed. *Bioscience Journal*, Uberlandia, V. 25, N.4: 135-142.
- Bock, W.J. (1974):** The avian skeleton-muscular system, in D.S. Farmer and J.R. King (eds.): *Avian Biology*. Vol.4, London: Academic Press. pp. 119-257.
- Brehm, H.K. Loeffler, K. and Komeyli, H. (1985):** Skull shape in the dog. *Anat. Histol. Embryol*. 14:324-331.
- Burden, F.; Szumito, J; Walocha, J; Klepacz, L.; Madel, B.; Dworzanski, W.; Klepacz, R.; Dworzanski, A.; Czekajska-Chehab, E. and Drop, A. (2012):** Morphology of the foramen magnum in young Eastern European adults. *Folia Morphol*. Vol.71, No.4: 205-216.

Chethan, P.; Prakash, K.G.; Mur-timanju, B.V.; Parashanth, K.U.; Prabhu, Latha V.; Saralaya, Vasudha, V.; Krishnamurthy, Ashwin; Somrdh, M.S. and Kimar, Ganesh (2012): Morphological Analysis and Morphometry of the Foramen Magnum: An Anatomical investigation. *Turkish Neurosurgery*, Vol. 22, No. 4: 416-419.

Chrószcz, A., Janeczek, M., Wojnar, M. and Pospieszny, N. (2006): Morphological analysis and morphometry of the foramen magnum of the american staffordshire terrier breed newborns. *Medycyna Weterynaryjna*, 62: 1002-1004.

Coulson, A and Lewis, N. (2008): An Atlas of Interpretative Radiographic Anatomy of the Dog and Cat. 2nd ed., Blackwell Publishing

Garcia-Perea, R. (1969): Pattern of postnatal development in skulls of Lynxes, Genus *Lynx* (Mammalia: Carnivora). *Journal of Morphology* 229: 241-254.

Getty, R. (1975): The Anatomy of the domestic animals. Vol. 1, 5th ed. Philadelphia, PA. W.B. Saunders, pp. 1427-1482. ISBN: 0-7216-4102-4.

Groves, C.P. (1999): The advantages and disadvantages of being domesticated (a keynote Address). *Perspectives in Human Biology*, 4: 1-12.

M. Janeczek, A. Chrószcz, V. Onar,

G. Pazvant and N. Pospieszny (2008): Morphological Analysis of the Foramen Magnum of Dogs from the Iron Age. *Anatomia, Histologia, Embryologia*, Volume 37, Issue 5

Kahvecioghu KO, Onar V, Alpak H and Pazvant G (2000): The morphometry of the foramen magnum in rabbits and its correlation with craniometric measurements. *Folia Veterinaria* 44: 62-69.

Karimi, I.; Hadipour, M.; Nibakht, P. and Motamedi, S. (2012): The lower Jawbone of Mehraban Sheep: A Descriptive Morphometric Approach. *World's Vet. J.* 2(4): 57-60.

Karimi, I.; Onar, V.; Pazvant, G.; Hadipour, M.M. and Mazahert, Y. (2011): The cranial morphologic characteristics of Mehraban sheep in western Iran. *Global Veterinaria* 6(2): 111-117.

Koch, D.A., Wiestner, T., Balli, A., Montavon, P.M., Michel, E., Schart, G. and Arnold, S. (2012): Proposal for a new radiological index to determine skull conformation in the dog. *Schweizer Archiv für Tierheilkunde*, 154 (5): 217-282.

Koenig, H,E, and Liebich, H.-G. (2007): *Veterinary Anatomy of Domestic Mammals (Textbook and Colour Atlas)* 3rd, Schattauer GmbH, Stuttgart, Germany.

Krüger, M., Hertwig, D.T., Jetschke, G. and Fischer, M.S. (2009): Evaluation of anatomical characters and question of hybridization with domestic cats in the wildcat population of Thuringia, Germany. *J Zool Syst Evol Res*, 47(3): 268–282.

Mihaylov, R.; Dimitrov, R.; Raichev, E.; Kostov, D.; Stamatova-Yiovecheva, K.; Zlatanova, D. and Bivolarski, B. (2013): Morphometric Features of the Head Skeleton in Brown Bear (*Ursus Arctos*) in Bulgaria. *Bulgarian Journal of Agricultural Science*, 19 (2): 331-337.

Monfared, A.L. (2013a): Some Aspects of Clinical Anatomy of the Head Region of the Caspian Miniature Horse and its Clinical Value During Regional Anesthesia. *Global Veterinaria* 10 (2): 214-218.

Monfared, A.L. (2013b): Gross Anatomical Measurements of the Head Region of the Iranian Native Cattle (*Bos taurus*) and Their Clinical Value for Regional Anesthesia. *Global Veterinaria* 10 (2): 219-222.

Monfared, A.L. (2013c): Clinical Anatomy of the Skull of Iranian Native Sheep. *Global Veterinaria* 10 (3): 271-275.

Monfared, A.L. (2013d): Applied Anatomy of the Head Regions of the One-humped Camel (*Camelus dromedaries*) and its Clinical Implications

During Regional Anesthesia. *Global Veterinaria* 10 (3): 322-327.

Monfared, A.L. (2013e): Gross Anatomy of the Head Region of the Iranian Native Horse and its Clinical Value During Regional Anesthesia. *Global Veterinaria* 10 (4): 403-407.

Monfared, A.L. (2013f): Craniometrical and Gross Anatomical Studies on the Iranian Buffaloes and Their Clinical Value for Regional Anesthesia. *Global Veterinaria* 10 (4): 427-431.

Monfared, A.L. (2013g): Anatomical Study of the Skull of the Adult Dogs and its Clinical Value During Regional Anesthesia. *Global Veterinaria* 10 (4): 459-463.

Monfared, A.L. (2013h): Macro-anatomical Investigation of the Skull of Golden Jackal (*Canis aureus*) and its Clinical Application During Regional Anesthesia. *Global Veterinaria* 10 (5): 547-550.

Monfared, A.L. (2013i): Anatomy of the Persian Cat's Skull and its Clinical Value During Regional Anesthesia. *Global Veterinaria* 10 (5): 551- 555.

Monfared, A.L. (2013j): Applied Anatomy of the Rabbit's Skull and its Clinical Application During Regional Anesthesia. *Global Veterinaria* 10 (6): 653-657

Monfared, A.L. (2013k): Anatomy of the Head Region of the Iranian Native

Donkeys and its Clinical Value During Regional Anesthesia. *Global Veterinaria* 10 (6): 658-662.

Moore, W.J. (1981): The Mammalian skull. Cambridge University Press. 343 pp.

Miller, M.S.; Christensen, G.C. and Evans, H.E. (1964): The skeletal system, skull, In anatomy of Dog. Pp. 6-49. W.B. Saunders Co., Philadelphia.

Muthukumar, N.; Swaminathan, R., Venkatesh, G. and Bhanumathy, S.P. (2005): A morphometric analysis of the foramen magnum region as it relates to the trans-condylar approach. *Acta Neurochir (Wein)*, 147: 889-895.

Muir III, W.W.; Hubbell, J.A.E., Skarda, R.T. and Bedbarski, R.M. (2001): Bloqueios anestésicos. In: Muie III (ed). *Manual de Anestesia Veterinaria*, 3rd ed. Artmed Sao Paulo. P 276-195 (cited by Barroso et al., 2009).

Nomina Anatomica Veterinaria (2005): International Committee on Veterinary Gross Anatomical Nomenclature. 5thed. Published by the Ed. Com. Hannover, Columbia, Gent, Supparo, USA.

Olopade, J.O. and Okandel, M.E. (2005): A study of some rostrafacial indices related to regional anaesthesia of the porcine: Implication as an ani-

mal model for dental research. *Nig. J. Physiol. Sci.* 25: 159-164.

Olopade, J.O. and Onwuka S.K. (2005): Morphometric study of the skull of the West African Dwarf goat from South West Nigeria. *Nigerian Veterinary Journal* Vol. 26 (2):18-21.

Olude MA, Olopade JO, Fatola IO and Onwuka SK (2009): Some aspects of the neurocraniometry of the African giant rat (*Cricetomys gambianus* Waterhouse). *Folia Morphologica* 68 (4): 224–227

Olude, M.A. and Olopade J.O. (2010): Morphometric Studies of the Axial Skeleton of the African Giant Rat (*Cricetomys gambianus*, Waterhouse) Part (I): Skull Typology. *J. Vet. Anat.*, Vol. 3, No. 2: 1-12

Onar, V. (1999): A morphometric study on the skull of the German shepherd dog (Alsatian). *Anat. Histol. Embryol.* 28, 253-256.

Onar, V., Özcan,S., Pazvant, G. (2001): Skull typology of the adult male Kangal dogs. *Anat. Histol. Embryol.* 30: 41-48.

Onar, V., Kahveciodlu, K. O. and Çebi, V. (2002): Computed tomographic analysis of the cranial cavity and neurocranium in the German shepherd dog (Alsatian) puppies. *Vet. Arhiv.* 72: 57-66.

Onar, V., Pazvant, G., Gezer Ince,

- N., Alpak, H., Janeczek, M. and Kiziltan, Z. (2013):** Morphometric analysis of the foramen magnum of Byzantine dogs excavated in Istanbul Yenikapi at the site of Theodosius harbor. *Mediterranean Archaeology and Archaeometry*, Vol. 13, No 1: 135-142.
- Özkan, Z.E. (2007):** Macro-anatomical investigations on the skeletons of mole-rat (*Spalax leucodon* Nordmann) III. Skeleton axiale. *Veterinarski arhiv* 77 (3), 281-289.
- Pasquini, C., Spurgeon, T. and Pasquini, S. (2007):** Applied anatomy of domestic animals, Systemic and regional approach. 11thed. Sudz Publishing.
- Rao, G.S. (1967):** Cranial capacity of adult bovine skull. *Journal of the Anatomical Society of India*, 16: 121-127.
- Saber, A. S. (1989):** Cranial capacity of the sheep and goat. *Assiut Vet. J.* 21(42):1-6
- Saber, A. S. (2015):** Clinical Anatomy of the mandible of three marsupial species (koala, Wombat, Wallaby). *J. Vet. Anat.* Vol.8, No.1: 1-11.
- Samul, O.M., Olopade, J.O., Korzner, M.R. and Onwuka, S.K. (2013):** Craniometric evaluation of some cranial indices of clinical significance in goats (*Capra hircus*) from the Middle-Belt Region of Nigeria -case for population surveillance and ecomigration. *European Journal of Zoological Research*, 2(4):89-97.
- Sandhu, P.S. and Dhingra, L.D. (1986):** Cranial capacity of Indian camel. *Indian Journal of Animal Sciences* 56(8): 870-872.
- Sarma, K. (2006):** Morphological and Craniometrical Studies on the Skull of Kagani Goat (*Capra hircus*) of Jammu Region. *Int. J. Morphol.* 24(3): 449-455.
- Sarma, K. and Samara, M. (2002):** Anatomy of the skull of Dum pig of Assam. *Indian J. vet. Anat.*, 79: 708-711.
- Simoens, R., Poles, R. and Lauwers, H. (1994):** Morphometric analysis of foramen magnum in Pekingese dogs. *American Journal of Veterinary Research*, 55: 33-39.
- Slatter, D. and Basher, T. (2003):** Orbit, in Slatter D, ed. *Textbook of Small Animal Surgery*, 3rd ed. Elsevier Science (USA) 1430-1453
- Smuts, G.I., Anderson, J.L. and Austin, J.C. (1978):** Age determination of the African lion (*Panthera leo*). *J.Zool.* 185: 115-146.
- Stacharski, M., Pezinska, K., Wroblewska, M., Wojtas, J and Baranowski, P. (2010):** The biometric characteristics of domestic cat skull in three stages of nits growth: Juvenile,

Subadult and Adult. Acta Sci. Pol., Zootechnica 9(3): 65-78.

Stefen, C. and Heidecke, D. (2012): Ontogenetic changes in the skull of the European wildcat (*Felis silvestris*, Schreber, 1777). Vertebrate Zoology 62 (2): 281-294.

Archana Sudhakar L. S. & Sharma, D. N. (1998): Anatomy of the skull of yak (*Bos gruniens*). Indian J. Vet. Anat. :10:5-9.

M Uddin, MHR Sarker, ME Hossain, MS Islam, MB Hossain, SK Shil (2013): Morpho-metric investigation of neurocranium in domestic cat (*Felis catus*). Bangl. J. Vet. Med.11 (1): 69-73

Uddin, M.M., Ahmed, S.S.U., Islam, Kh.N. and Islam, Md. M. (2009): Clinical anatomy of the head region of the Black Bengal goat in Bangladesh. Int. J. Morphol. 27(4): 1269-1273.

Yahaya, A., Olopade, J.O., Kwari, D. and Wiam, I.M. (2012): Osteometry of

the skull of one-humped camels. Part I: immature animals. IJAE, Vol.117, n: 23-33.

Yahaya, A., Olopade, J.O., Kwari, H.D. (2013): Morphological Analysis and Osteometry of the Foramen Magnum of the One-Humped Camel (*Camelus dromedarius*). Anat. Histol. Embryol. 42: 155–159

Zuccarelli Micah D. (2004): Comparative morphometric analysis of captive vs. wild African lion (*Panthera leo*) skulls. Bios, Vol.75, No.4: 131-138.

Websites

1. http://www.skullsunlimited.com/userfiles/image/variants_large_3342.jpg (Retrieved 16/2/2014).
2. <http://bigcatrescue.org/flat-headed-cat-facts>. (Retrieved 25/7/2014).
3. <http://www.arkive.org/flat-headed-cat/prionsilurus-planiceps/>(Retrieved 6/5/2014).
4. <http://en.wikipedia.org/wiki/marsupial> (Retrieved 16/2/2014).

Table (1): Australian domestic flat-headed cat skull measurements

No	Parameter	Mean	SD	Max	Min
1	Skull length (cm)	10.1	0.9	11.7	8.7
2	Skull width (cm)	7.2	0.4	7.8	6.2
3	Skull weight (gm.)	33.1	7.6	45	19
4	Cranial length (cm)	7.8	0.6	8.9	6.5
5	Cranial width (cm)	4.3	0.2	4.8	4.1
6	Foramen magnum height (cm)	1.1	0.2	1.3	0.6
7	Foramen magnum width (cm)	1.4	0.2	1.6	1.0
8	Cranial capacity (cc)	30.0	5.2	38	21.5
9	Facial length (cm)	2.3	0.3	2.8	1.9
10	Facial width (cm)	6.7	0.3	7.4	6.4
11	Orbital height (cm)	2.9	0.3	3.3	2.3
12	Orbital width (cm)	2.5	0.2	2.8	2.3
13	Inter-orbital distance (rostral) (cm)	2.6	0.3	3.1	2.1
14	Inter-orbital distance (middle) (cm)	2.2	0.2	2.5	1.8
15	Inter-orbital distance (caudal) (cm)	5.9	0.2	6.0	2.7
16	Infra-orbital foramen distance (cm)	2.9	0.2	3.2	2.7
17	Infra-orbital to canine root (cm)	1.6	0.4	2.6	1.2
18	Infra-orbital to premolar I (cm)	0.9	0.2	1.1	0.7
19	Orbital capacity (gm.)	7.9	1.7	11	5

Table (2): Australian domestic Round-headed skull measurements

No	Parameter	Mean	SD	Max	Min
1	Skull length (cm)	8.2	0.7	9.8	7.3
2	Skull width (cm)	5.8	0.5	7.1	5.1
3	Skull weight (gm.)	17.1	5.4	27	9
4	Cranial length (cm)	6.2	0.5	7.1	5.5
5	Cranial width (cm)	4.1	0.2	4.4	3.6
6	Foramen magnum height (cm)	1.1	0.2	1.9	1.0
7	Foramen magnum width (cm)	1.3	0.2	1.9	1.1
8	Cranial capacity (cc)	25.2	3.8	31.6	14.5
9	Facial length (cm)	1.9	0.3	2.8	1.5
10	Facial width (cm)	5.4	0.6	6.8	4.4
11	Orbital height (cm)	2.4	0.3	2.8	1.9
12	Orbital width (cm)	2.2	0.2	2.5	1.9
13	Inter-orbital distance (rostral) (cm)	2.2	0.3	2.5	1.6
14	Inter-orbital distance (middle) (cm)	1.7	0.2	1.9	1.4
15	Inter-orbital distance (caudal) (cm)	2.9	0.7	4.5	2.3
16	Infra-orbital foramen distance (cm)	2.3	0.3	2.8	1.9
17	Infra-orbital to canine root (cm)	1.0	0.2	1.4	0.8
18	Infra-orbital to premolar I (cm)	0.7	0.2	1.1	0.3
19	Orbital capacity (gm.)	5.0	1.6	8.5	3

Table (3): Measurements of the flat-headed cat mandible.

No	Parameters (cm)	Mean	DS	Max	Min
1	Mand. Length	6	0.6	7	5
2	Mand. Wt. (gm.)	9.6	3.1	15	4
3	Ment. F - C Mand B	4.3	1.3	5.5	0.5
4	Ros. Ment. F – C Ment. F	0.5	0.1	0.7	0.4
5	Ros. Ment. F – Incisive A	0.9	0.1	1.1	0.7
6	Mand F – Mand CB	1.3	0.4	1.8	0.1
7	Mand F – Angle Mand	1.5	0.2	1.7	1.2
8	Mand F – Ven. Bor Man	0.7	0.2	0.9	0.4
9	Mand Height	2.9	0.3	3.5	2.4
10	Cond. Proc – Ven Bor. Man	1.5	0.2	1.8	1.2
11	Cron. Proc – Cond. Proc	1.6	0.2	1.7	1.2
12	Diastema	0.9	0.3	1.4	0.6
13	Inter. Mand. Dis.	2.9	0.4	3.8	2.4

Table (4): Measurements of the round-headed cat mandible.

No	Parameters (cm)	Mean	DS	Max	Min
1	Mand. Length	4.4	0.6	5.5	3.7
2	Mand. Wt. (gm.)	4	1.6	8	2
3	Ment. F - C Mand B	3.6	0.4	4.3	2.9
4	Ros. Ment. F – C Ment. F	0.4	0.1	0.5	0.2
5	Ros. Ment. F – Incisive A	0.7	0.2	1	0.4
6	Mand F – Mand CB	0.9	0.2	1.2	0.6
7	Mand F – Angle Mand	0.9	0.3	1.6	0.1
8	Mand F – Ven. Bor Man	0.4	0.1	0.7	0.3
9	Mand Height	2.2	0.3	2.6	1.8
10	Cond. Proc – Ven Bor. Man	1.1	0.2	1.6	0.8
11	Cron. Proc – Cond. Proc	1.1	0.2	1.7	0.7
12	Diastema	0.7	0.2	1.1	0.5
13	Inter. Mand. Dis.	2.0	0.6	2.8	0.7

Table (5, A): Flat-headed skull average indices.

Indices	Mean	SD	Max	Min
Skull index	71.1	4.4	80.80	64.96
Cranial index	56.0	4.0	63.08	46.07
Facial index	298.1	34.0	347.37	228.57
Orbital index	86.2	9.1	104.35	76.67
Foramen magnum index	128.5	30	216.66	90.9

Table (5, B): Round-headed skull average indices.

Indices	Mean	SD	Max	Min
Skull index	71.3	2.4	75.6	67.8
Cranial index	66.6	4.9	73.9	59.2
Facial index	279.8	31.9	326.3	207.1
Orbital index	92.5	7.1	115	85.7
Foramen magnum index	128.3	18.8	190	110

Table (6): Measurements between the mandibular foramen (Mand. For.) and caudal border of the mandible and between mandibular foramen and ventral border (base) of the mandible in some animal species.

Animals	Authors	Mand. For. To Caudal border of mandible (cm)	Mand. For. to ventral border of mandible (cm)
Caspian Miniature horse	Monfared (2013a)	4.4±0.03	5.79±0.57
Iranian native cattle	Monfared (2013b)	2.9 ±0.72	5.2±0.37
One-humped camel	Monfared (2013c)	3.7±0.11	3.88±0.37
Native sheep	Monfared (2013d)	0.86±0.03	2.99±0.03
Native horse	Monfared (2013e)	4.8±0.62	6.3±1.34
Iranian buffalo	Monfared (2013f)	2.97±0.26	5.5±0.31
Dog	Monfared (2013g)	1.1±0.09	0.96±0.57
Rabbit	Monfared (2013h)	1.5±0.23	0.87±0.09
Golden Jackal	Monfared (2013i)	1.05±0.02	1.2±0.04
Persian cat	Monfared (2013j)	0.65±0.36	0.8±0.66
Native donkey	Monfared (2013k)	3.5±0.02	4.7±1.22
West African dwarf goat	Olopade et al. (2010)	1.57±0.44	-
Pig	Olopade&Okandely(2010)	2.83±0.34	9.34±0.95
Black Bengal goat	Uddin et al. (2009)	0.9±0.15	3.64±0.23
Goat	Samuel et al. (2013)	2.54±0.56	4.17±1.03
Koala	Saber (2014)	1.3±0.75	2.6±1.84
Wombat	Saber (2014)	2.1±1.48	2.25±1.50
Wallaby	Saber (2014)	2.7±1.45	0.87±0.57

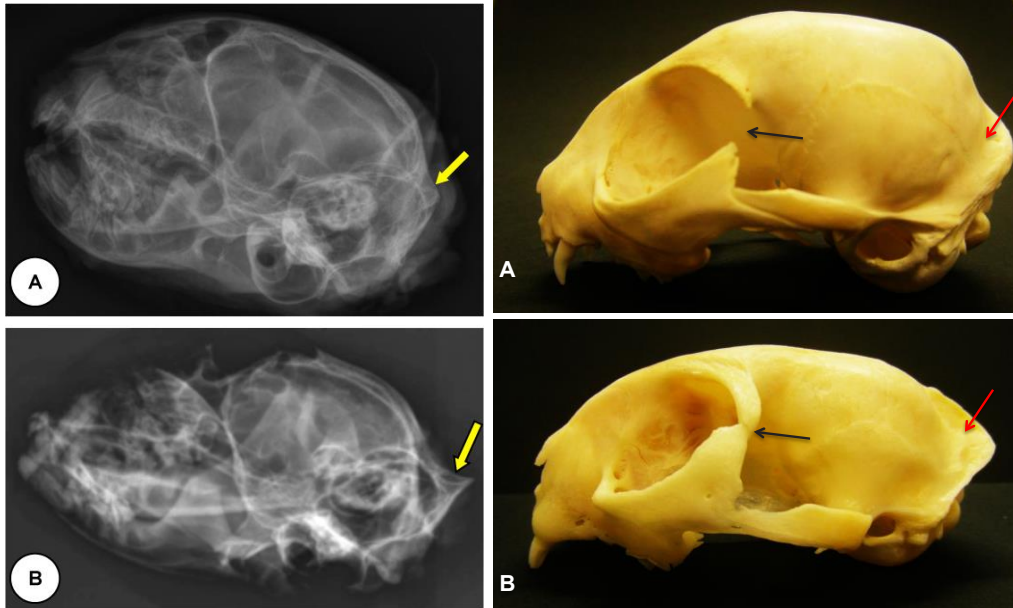


Fig (1): Lateral view of the Australian domestic round-headed cat skull, X-ray image right, and skull left upper tier (A) and the Australian domestic flat-headed cat skull, right and left respectively, lower tier (B) showing the well developed external sagittal crest (yellow and red arrows), Black arrows point out to the complete fusion of the zygomatic process of the frontal bone with the zygomatic arch in flat-headed skull.

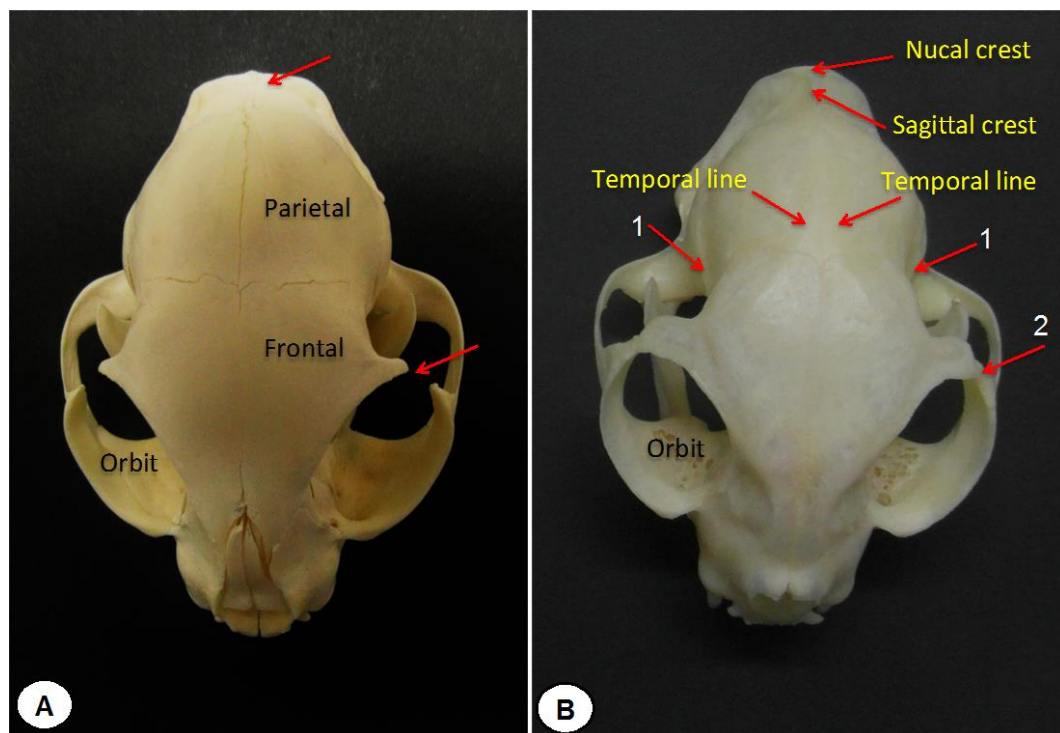


Fig (2): Dorsal view of the Australian domestic round-headed cat (A) and the Australian domestic flat-headed cat skull (B) showing the morphological differences: 1 Postorbital constriction, 2 fusion of the zygomatic process of the frontal bone with the zygomatic arch, the prominent external sagittal crest arising from the nuchal crest and lengthening of the cranium.

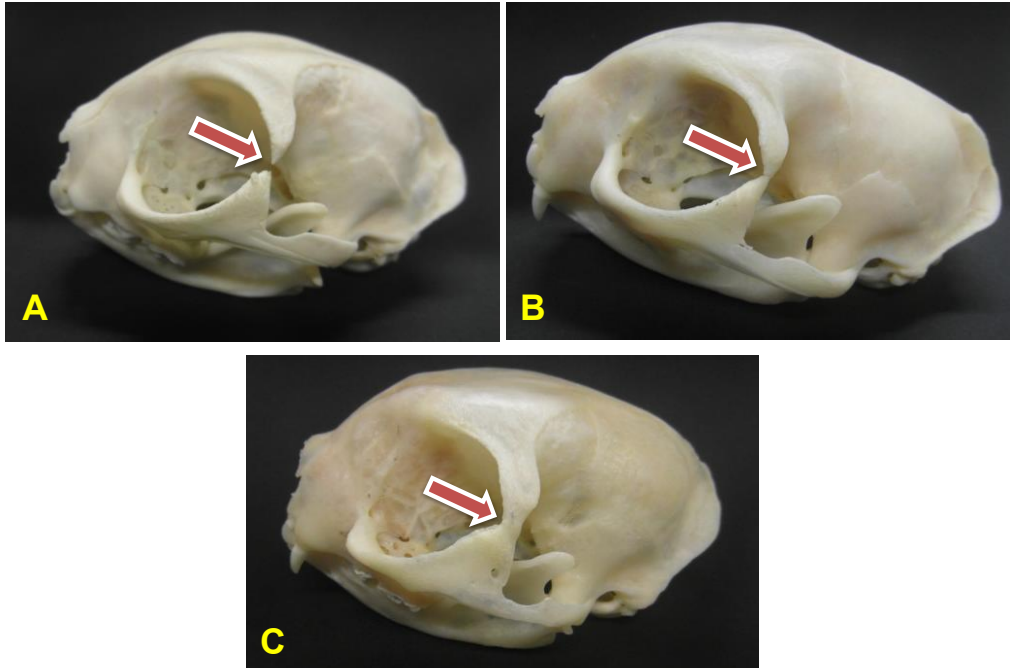


Fig (3): A-C different stages of the ossification of the orbital ligament in the flat-headed cat skull (complete closure of the orbit in C)

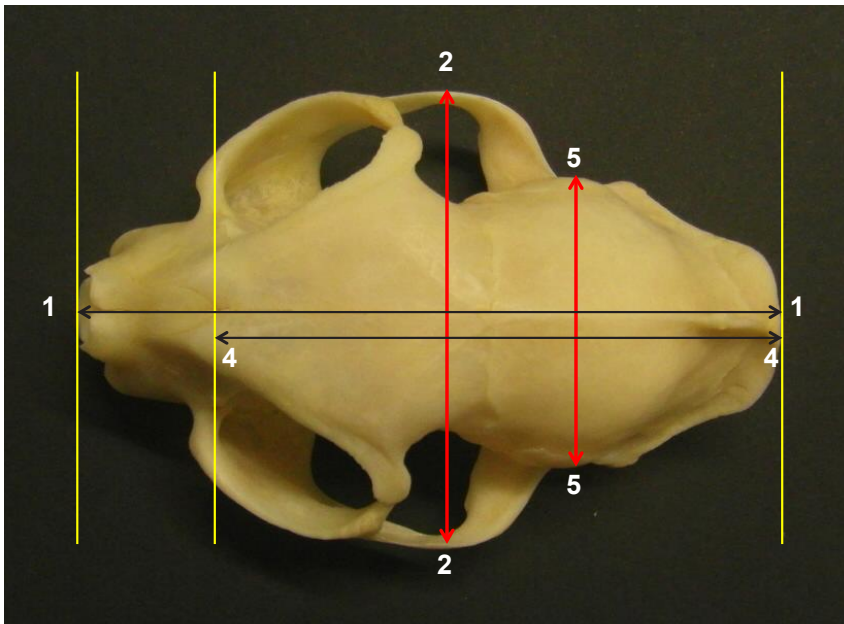


Fig (4): Dorsal view of the skull of the Australian domestic, flat-headed cat skull showing the measurements: 1-1 skull length, 2-2 skull width, 4-4 cranial length, 5-5 cranial width.

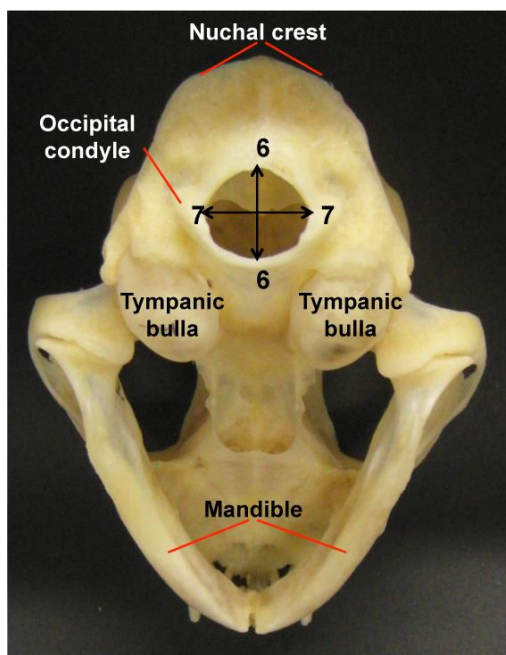


Fig (5): Ventro-caudal view of the Australian domestic flat-headed cat skull base showing the measurements: 6-6 foramen magnum height, 7-7 foramen magnum width.

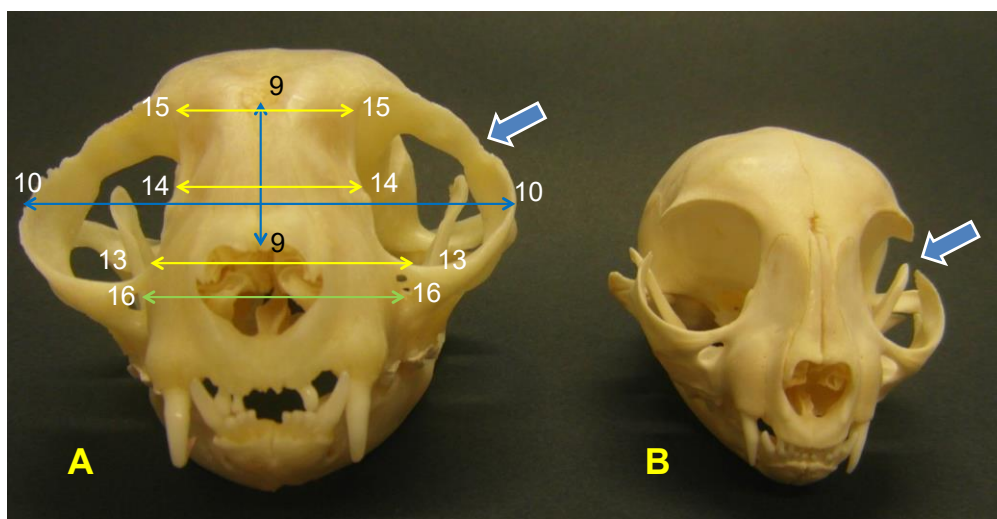


Fig (6): Rostral view of the Australian domestic flat-headed cat skull (A) and the domestic round-headed cat (B) showing the measurements: 9-9 facial length, 10-10 facial width, 13-13 rostral inter-orbital length, 14-14 middle inter-orbital length, 15-15 caudal inter-orbital length, 16-16 distance between the infra-orbital foramina. The arrows point out to the bony closure of the orbital rim in the Australian flat-headed cat skull and the normal incomplete rim in the round-headed house cat. Note the double infra-orbital foramina on the left side of image (A).

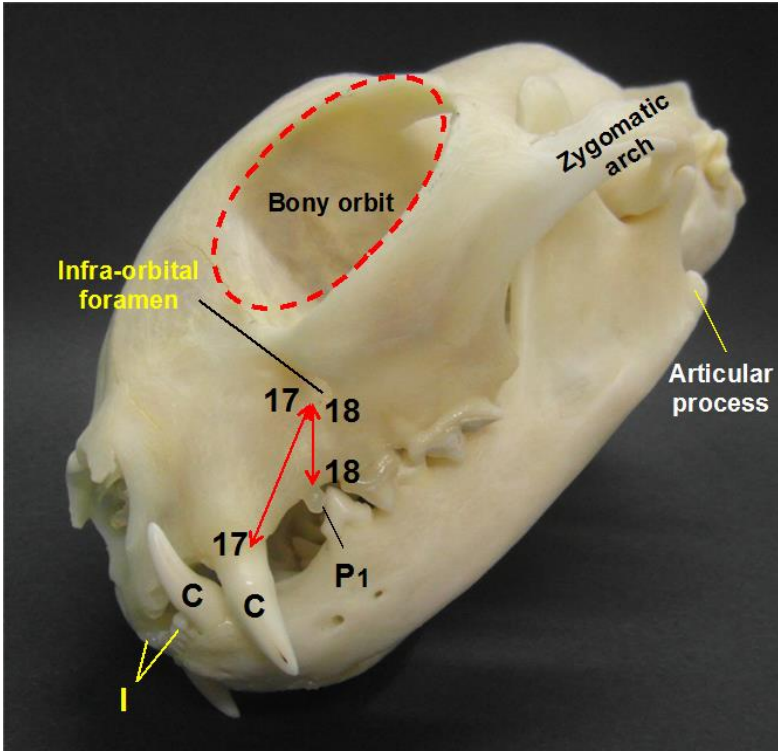


Fig (7): Rostro-lateral view of the Australian flat-headed domestic cat skull showing the measurements: 17-17 distance between infra-orbital foramen and the canine tooth, 18-18 distance between infra-orbital foramen and the first upper premolar (P1).

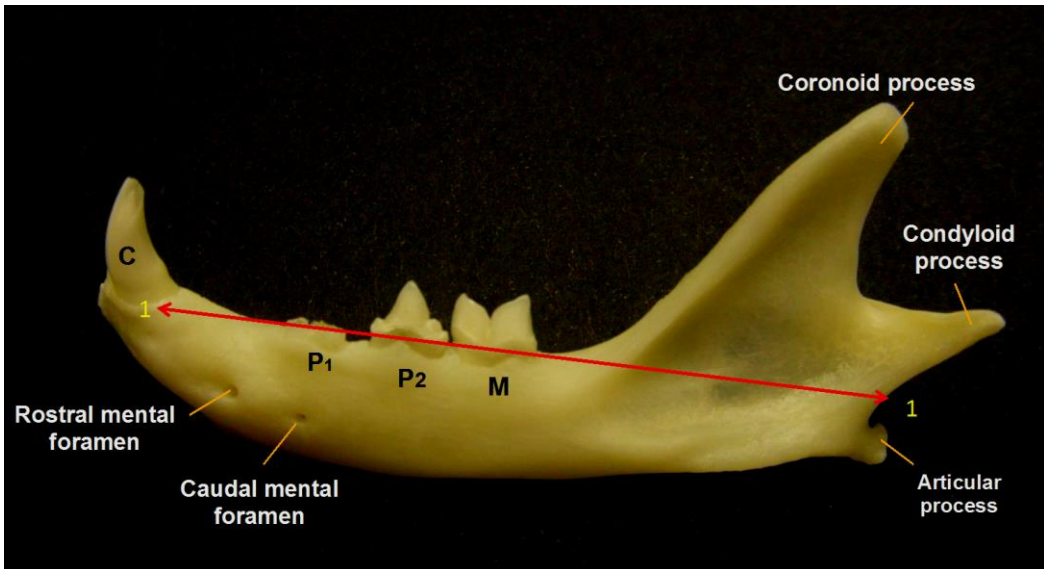


Fig (8): Lateral view of the left ramus of the mandible of the Australian flat-headed domestic cat showing the measurements: 1-1 mandibular length.

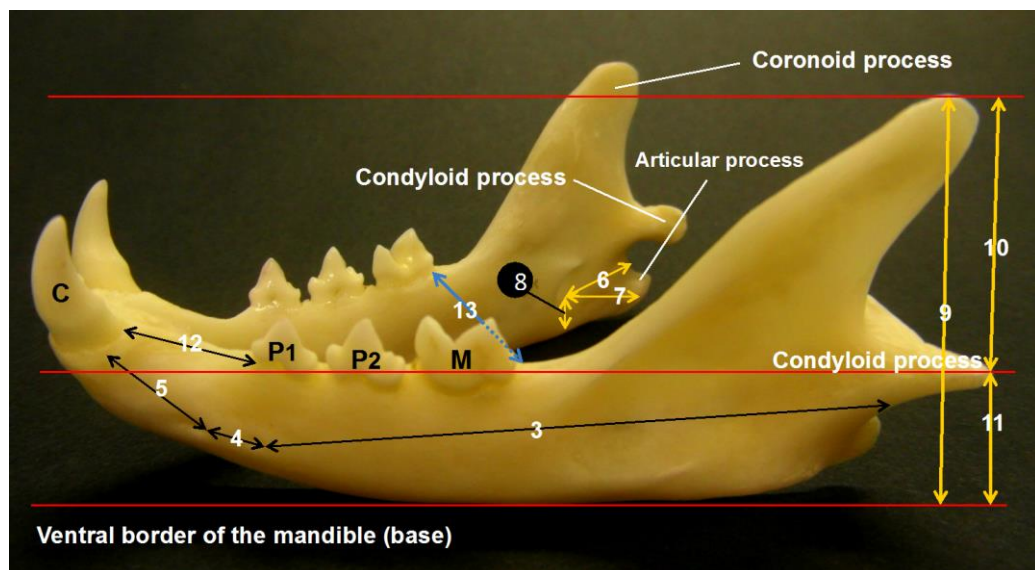


Fig (9): Lateral view of the Australian flat-headed domestic cat skull showing the measurements: 3 caudal mental foramen to caudal border of the mandible, 4 distance between caudal and rostral mental foramina, 5 rostral mental foramen to canine alveolus, 6 mandibular foramen to caudal border of the mandible, 7 mandibular foramen to angle of the mandible, 8 mandibular foramen to ventral border of the mandible, 9 mandibular height, 10 coronoid to condylod process, 11 condylod to ventral border of the mandible, 12 diastema, 13 intermandibular distance at the level of the last mandibular teeth (M).

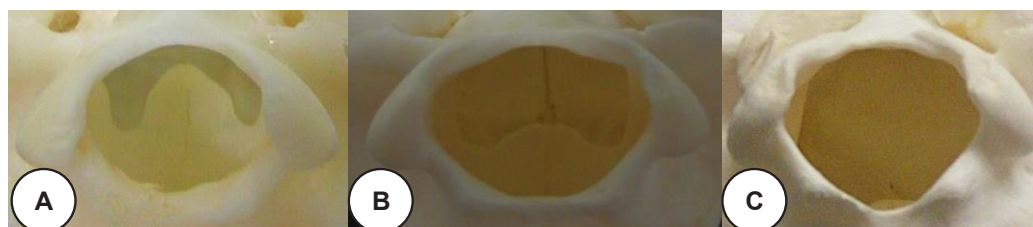

Fig (10): Sowing the morphological variation of the foramen magnum in the Australian cat skulls. A round shape, B oval shape, C triangle shape.

Corresponding Author:

Prof. Dr. Ashraf Sobhy Mohamad Saber, Fac. Vet. Med., Univ. of Sadat City, EGYPT

Saberashraf_2@yahoo.com